Aesth. Plast. Surg. 27:258–264, 2003
DOI: 10.1007/s00266-003-3065-3

Aesthetic Plastic Surgery
© 2003 Springer-Verlag New York Inc.

Anatomy of the SMAS Revisited

Alireza Ghassemi, Andreas Prescher, Dieter Riediger, and Hubertus Axer

Aachen, Germany,

Abstract. Despite the relevance of the superficial musculoaponeurotic system (SMAS) in facial rejuvenation a clear anatomic definition of the SMAS is still lacking. Therefore, the morphology of the SMAS in 18 cadavers was investigated using different macroscopic and microscopic techniques. The region-specific anatomy of the SMAS is described in the forehead, parotid, zygomatic, and infraorbital regions, the nasolabial fold, and the lower lip. The SMAS is one continuous, organized fibrous network connecting the facial muscles with the dermis. It consists of a three-dimensional scaffold of collagen fibers, elastic fibers, and fat cells. Two different types of SMAS morphology were demonstrated: type 1 SMAS architecture is located lateral to the nasolabial fold with relatively small fibrous septa enclosing lobules of fat cells, whereas type 2 architecture is located medial to the nasolabial fold, where the SMAS consists of a dense collagen–muscle fiber meshwork. Overall, it was demonstrated that different facial regions show specific morphological characteristics, and thus region-specific surgical interventions may be necessary in facial rejuvenation.

Key words: Superficial musculoaponeurotic system—Collagen—Fiber architecture—Cosmetic surgery

Introduction

The CNS, mimetic muscles, their tendon fibers, and the skin comprise a functional unit. The anatomy of facial soft tissue plays an important role in understanding this functional entity. The concept of the superficial musculoaponeurotic system (SMAS) was first introduced by Mitz and Peyronie [18], and SMAS surgery in face-lifting procedures is now a common approach [14]. However, a clear anatomic definition of the SMAS is still lacking. Table 1 gives an overview of the different and controversial definitions of the SMAS. The intention of this study was to critically reinvestigate the macroscopic and microscopic morphology of the SMAS using different anatomic techniques.

Correspondence to Alireza Ghassemi, ZMKPG, universitätsklinikum der RWTH Aachen, Pauwelsstr. 30, D-52057 Aachen, Germany; *email:* arghassemi@yahoo.com

Materials and Methods

The soft tissue of the faces of 18 fresh cadavers between 66 and 92 years of age (9 female; 9 male) which had been donated for anatomical study was macroscopically and microscopically analyzed. The right side of the face was dissected macroscopically whereas histological samples were taken from the left side.

Macroscopic Dissection

The incision line of the skin was planned differently from the standard face lift. The incision followed the hair line extending downward to the ear anterior to the tragus. It was then curved around the inferior aspect of the ear lobe. Here a vertical incision toward the clavicle was made. The sharp dissection of the skin was forwarded to the midsagittal plane.

The SMAS was then elevated. The dissection of the SMAS in the pretragal area and over the parotid gland was aided by using the parotid fascia as landmark. Special interest was paid to that point where the facial nerve branches became related to the SMAS layer. All peripheral branches were carefully dissected. Posteriorly, it was followed to the stylomastoid foramen.

Table 1. Definitions of the SMAS

Definition	Reference
Superficial fascia or tela subcutanea	[9]
SMAS: continuous fibrous net sending several extensions out to the dermis; comprises all the attachments from the facial muscles to the dermis; in continuity with the posterior part of the frontalis muscle and with the platysma	[18]
SMAS: Fascia superficialis Fascia parotidea: fibrous degenerated platysma continuous with the platysma	[15]
SMAS: distinct fibromuscular layer composed of the platysma muscle, parotid fascia and fibromuscular layer covering the cheek	[27]
Layers of face: 1. Skin 2. Subcutaneous fat 3. Superficial fascia (SMAS): extension of the superficial cervical fascia 4. Mimetic muscles 5. Deep facial fascia (parotidomasseteric fascia) 6. Retaining ligaments	[24]
Layers of face: 1. Dermis 2. Fascial fatty layer: subcutaneous tissue with dense network of fibrous septa 3. SMAS: distinct musculoaponeurotic layer in continuity with the platysma 4. Separate parotid fascia	[8]
Three layers of SMAS: 1. Layer of SMAS fascia superficial to musculature 2. Layer of muscle 3. Deep layer of the SMAS extensively attached to the skeleton	[7]
Skin is connected to SMAS by fibrous septa and SMAS has intimate connections to mimetic muscles; the SMAS is a composite tissue comprising collagen, elastin, fat cells, and interstitial fluid	[12]

Histologic Preparation

Six distinct locations of the face were defined for histologic samples (Fig. 1): forehead, parotid, zygomatic, and infraorbital region, nasolabial fold, and lower lip. For comparison with the subcutaneous morphology of the body, additional samples were taken from the deltoid region, which was arbitrarily selected. Two tissue blocks of 0.5×3 cm were cut out of the faces at each of these locations and fixed in 4% buffered formalin solution for 1 week. The first block was embedded in paraffin and sliced at 10 μm. The sections were stained with a modified Masson–Goldner's trichrome stain, eosin–hematoxylin, and resorcin–fuchsin for conventional microscopy. The second block was sectioned with a cryostat microtome at a thickness of 100 μm. These sections were stained with picrosirius red (0.1 g sirius red F3B per 100 ml saturated aqueous picric acid; sirius red F3B, direct red 80, CI number 35780; Aldrich Chemie, Steinheim, Germany) and with eosin. The picrosirius staining selectively labels collagen fibers [16] and enhances the birefringent properties of collagen fibers used for polarization microscopy (Leica TCS IRBE). The eosin stain has fluorescent properties and can be imaged with confocal laser scanning microscopy (Leica TCS NT, Leica Microsystems, Heidelberg, Germany). The confocal microscope allows the making of single optical sections through a fluorescent sample. Serial optical sections (a z-series) can be used to perform a 3D reconstruction of a volume and thus give information about the three-dimensional architecture of collagen fibers in the SMAS [2,3].

Results

Macroscopic Dissection

The subcutaneous fatty layer is of variable thickness and envelops the mimetic muscles. Anatomic dissection deep to the SMAS demonstrated a very thin layer anterior to the parotid gland. At this point the branches of the facial nerve became closely related to the SMAS and were in danger of being injured by sharp dissection. The cadavers, which were elderly, had delicate skin, scant subcutaneous tissue, and a thin SMAS. In most cases, the main trunk of the facial nerve bifurcated inside the parotid gland and then formed the facial plexus. The following branches were identified: temporal, zygomatic, buccal, marginal mandibular, and cervical.

Histologic Description

For comparison of the morphology of the SMAS with the subcutaneous tissue of another part of the

Fig. 1. Six locations of cross-sections for histological examination: I: forehead region, II: parotid region, III: zygomatic region, IV: infraorbital region, V: nasolabial fold, and VI: lower lip.

body samples were taken from the deltoid region (Fig. 2). The deltoid muscle is completely enveloped by a thick deltoid fascia which completely separates the subcutaneous tela from the muscle compartment. The subcutaneous tissue is separated by a few small fibrous septa which incompletely envelop large lobules of fat cells. In contrast, the subcutaneous morphology of the face is more organized than that of the body.

I: Forehead region. In the region of the forehead (Fig. 3) vertical fibrous septa consisting of elastic and collagen fibers anchor in the dermis of the skin. Few horizontal septa are found in this region. In the depth of the subcutaneous tissue a compact band of muscle constitutes the deep border of this compartment. The fibrous septa insert at the collagenous envelope of this muscle band which is part of the frontal belly of the occipitofrontalis muscle. In polarized light microscopy of thick histological sections, the three-dimensional architecture of the fibrous septa becomes apparent (Fig. 4). The fibrous septa surround lobules of fat cells which constitute distinct compartments of small fat pads. Few branches of nerves can be found in the depth of the subcutaneous tissue, most of them associated with muscle.

II: Parotid region. In the superficial part of the fatty layer of the tela subcutanea of the parotid region (Fig. 5) vertical septa are connected to the dermis of the skin forming a superficial architecture of rectangular lobules of fat cells. In contrast, in the deeper part of the subcutaneous connective tissue more horizontal septa are found enveloping larger, flat lobules of fat cells. Thus, the subcutaneous tissue is divided into a superficial and a deep architectural zone. Nevertheless, the fibrous septa form a continuous network of fibers. The deep border of the tela subcutanea consists of the parotid fascia, which is also built from horizontal fibrous septa, but can be easily separated from the subcutaneous septa. No skeletal muscle fibers and only a few nerves were observed.

III: Zygomatic region. In the zygomatic region the architecture of the SMAS is similar to that of the parotid region (Fig. 6): superficially vertical and horizontal fibrous septa form rectangular fat lobules, whereas in the deeper layer the horizontal septa prevail and the fat lobules are flat. The fibrous septa are anchored in the periosteum covering the zygomatic bone or are attached to the zygomaticus major muscle. Nerve branches can be found in the fibrous septa in the deeper layer of the subcutaneous tissue.

IV: Infraorbital region. The infraorbital region is characterized by a compact band of the orbicularis oculi muscle which constitutes the deep border of the subcutaneous tissue (Fig. 7). Small vertical and horizontal fibrous septa connect the muscle with the skin and envelop large rectangular lobules of fat cells. More elastic fibers can be found in the superficial than in the basal septa and, superficially, the lobules of fat cells are larger than basally. In the middle of the subcutaneous tissue, small bundles of muscle fibers are attached to the fibrous septa. These are part of the orbicularis oculi muscle. Branches of nerves are found in the entire tela subcutanea, but they are mostly innervating muscle fibers.

V: Nasolabial fold. Here, two architectural patterns are adjacent to one another forming the nasolabial fold (Figs. 8 and 9). Lateral to the nasolabial fold small vertical fibrous septa envelop vertically oriented, tall lobules of fat cells. In the depth of the nasolabial fold lies the buccinator muscle, to which most nerve fibers are attached.

Medial to the nasolabial fold a completely different architecture can be seen: almost no fibrous septa and no fat lobules are found in the upper lip. In contrast, it consists of a meshwork of intermingled collagen and elastin fibers, skeletal muscle fibers, and fat cells. The muscle fibers reach directly to the dermis of the skin. Between these fibers many nerve branches can be observed throughout the tela subcutanea. The basal border of this compartment is a compact muscle, the orbicularis oris.

VI: Lower lip. In the lower lip the architecture of the subcutaneous tissue is quite similar to the upper lip (Fig. 10); a meshwork of connective tissue fibers, muscle fibers, and fat cells extend from the orbicularis oris muscle basally directly to the dermis.

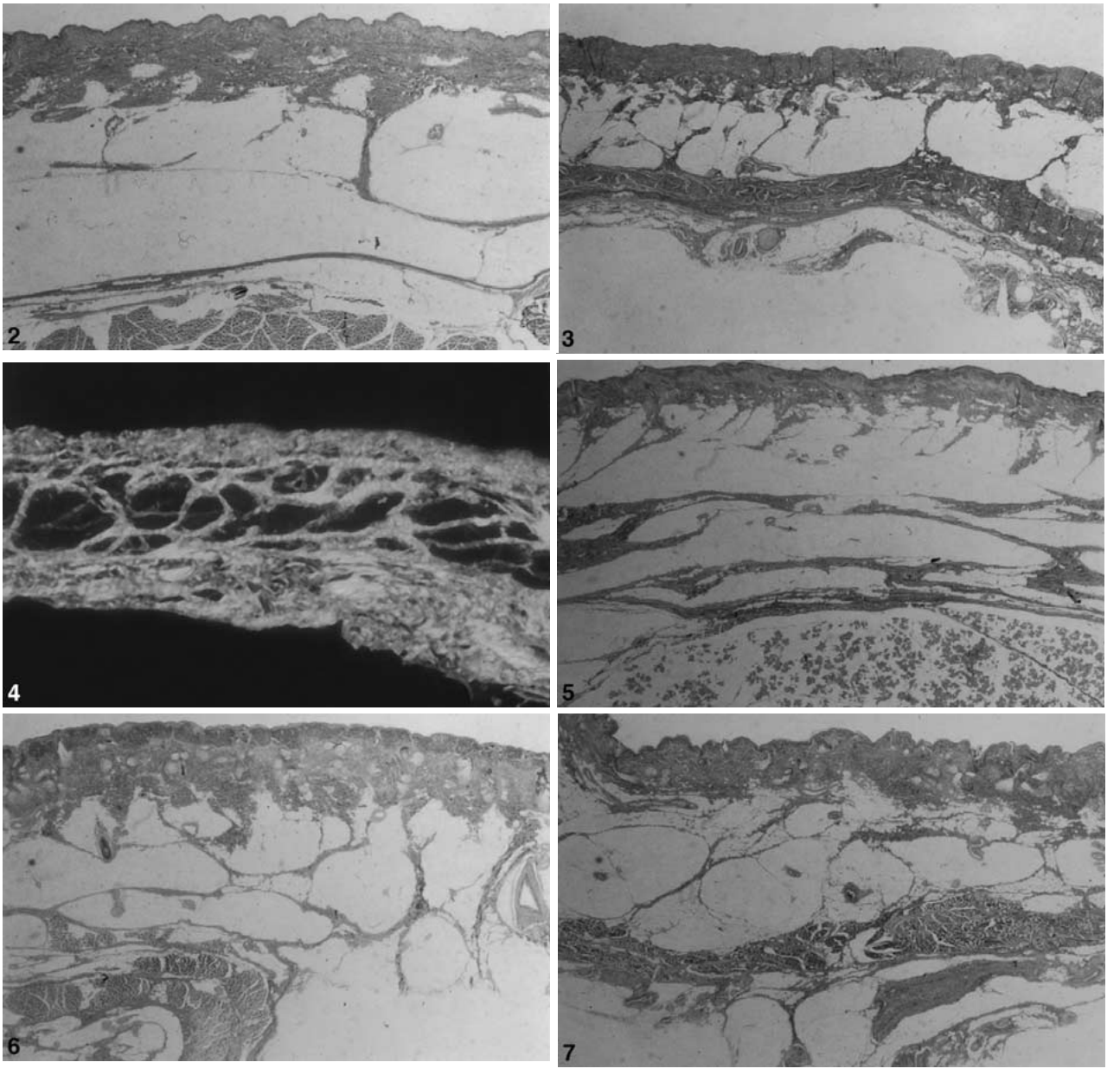

Fig. 2. Subcutaneous morphology of the deltoid region. The subcutaneous fat is completely separated from the muscle by the fascia. Masson–Goldner's trichrome, ×2.8.
Fig. 3. Cross-section of the forehead region. Masson–Goldner's trichrome, ×2.8.
Fig. 4. Cross-section of the forehead region. Picrosirius red in polarized light, ×2.8.
Fig. 5. Cross-section of the parotid region. Masson–Goldner's trichrome, ×2.8.
Fig. 6. Cross-section of the zygomatic region. Masson–Goldner's trichrome, ×2.8.
Fig. 7. Cross-section of the infraorbital region. Masson–Goldner's trichrome, ×2.8.

Discussion

The subcutaneous fat of the body is completely separated from the muscle compartment by an investing layer of fascia enveloping all muscles of the body. In the face, however, the muscles have connections to the skin in order to enable the complex movements of the skin for facial expressions. Thus, the subcutaneous tissue plays a prominent functional role because it contains the tendon fibers of the facial muscles. The extraordinary functional importance of this subcutaneous compartment is reflected in the concept of the superficial musculo-aponeurotic system, the SMAS. Thus an anatomic definition of the SMAS must highlight its functional unity. We would suggest the following definition in accordance with Har-Shai et al. [12,13]:

The SMAS is one continuous and organized fibrous network in the face connecting the facial

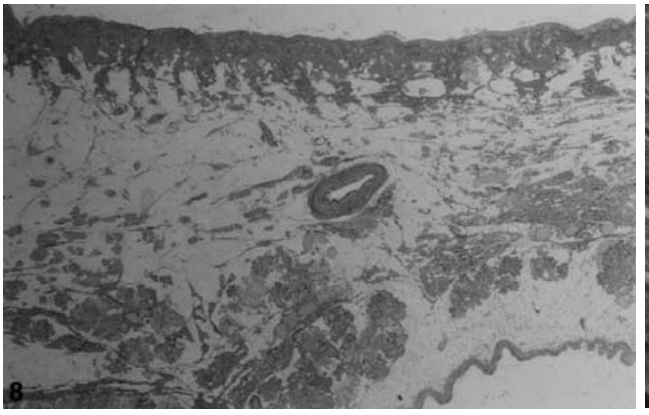

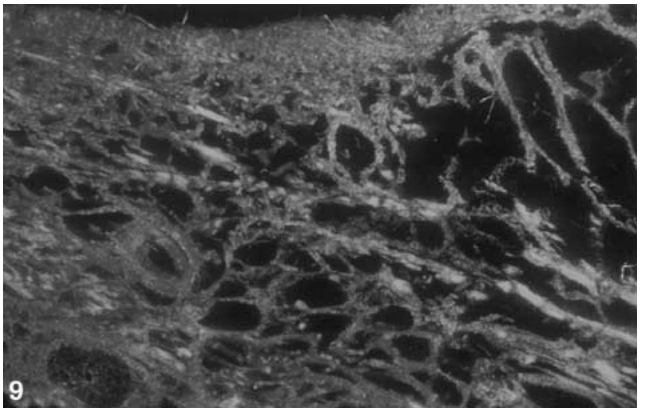

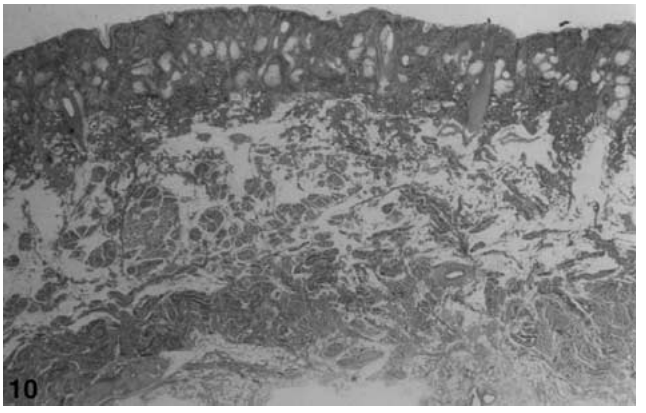

Fig. 8. Cross-section of the nasolabial fold. Masson–Goldner's trichrome, ×2.8.
Fig. 9. Cross-section of the nasolabial fold. Picrosirius red in polarized light, ×2.8.
Fig. 10. Cross-section of the lower lip. Masson–Goldner's trichrome, ×2.8.

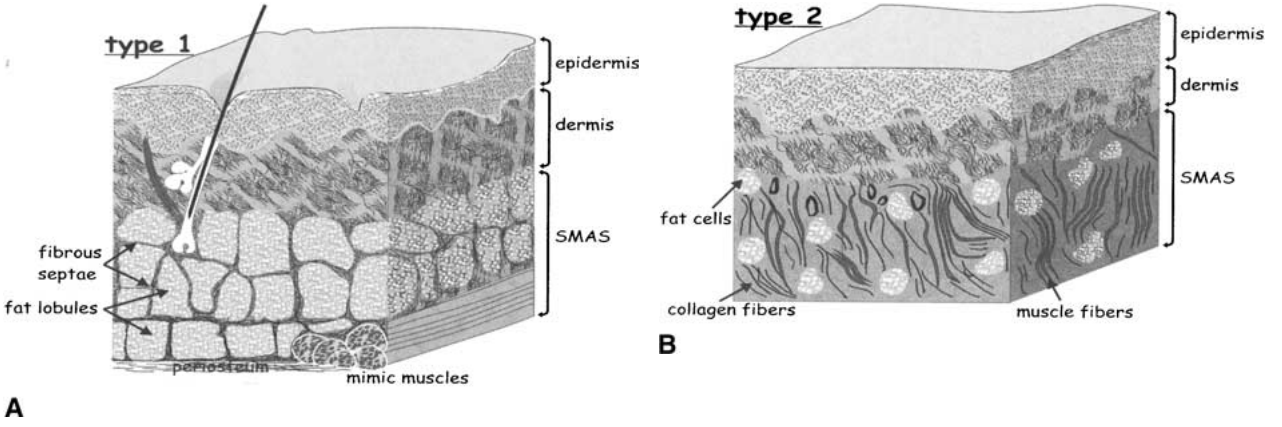

Fig. 11. Two models of SMAS architecture. (Top) Type 1 and (bottom) type 2.

muscles with the dermis and consists of a three-dimensional architecture of collagen fibers, elastic fibers, fat cells and muscle fiber.

Two different architectural models of the SMAS can be described (Fig. 11). *Type 1:* The common architecture in the posterior part of the face is a meshwork of fibrous septa which envelops lobules of fat cells. These lobules can act as small pads with viscoelastic properties [12,13]. The interconnecting fibrous network is anchored to the periosteum [19] (retaining ligaments) or connected to the facial muscles. The meshwork character of the collagen architecture has dynamic properties. This kind of SMAS morphology was found in the forehead, in the parotid, zygomatic, and infraorbital regions, and in the lateral part of the nasolabial fold. Here an abrupt border to a second kind of SMAS architecture was observed.

Type 2: This second architectural model is a meshwork of intermingled collagen and elastic fibers and muscle fibers. The muscle fibers reach up to the dermis of the skin. Separate and distinct lobules of fat are not observed. Instead, fat cells are interposed between this collagen fiber–muscle meshwork. This

type 2 SMAS morphology is found in the upper and lower lip, and here a specific function can be supposed. The complex meshwork of muscle fibers and collagen has a direct relationship to movements of the oral skin. Between the muscle fibers multiple nervous branches can be found demonstrating the high degree of innervations in this region. Besides its functional meaning the SMAS is a compartment which contains nerves and vessels. From a surgical point of view the facial nerve is of highest importance because lesions of the facial nerve have to be carefully avoided [4,6,25]. The facial nerve leaves the skull at the stylomastoid foramen and splits inside the parotid gland into its peripheral branches. These penetrate the parotid fascia, and at this point they become related to the SMAS. Generally, nerve fibers increase in number from the ear to the mouth, and anterior to the parotid gland they are located more superficially [1]. The proximity of the facial nerve to the deep layer of the SMAS at this point was first noted by Mitz and Peyronie [18] and was confirmed in this study in the histologic as well as the macroscopic preparations.

In addition, the SMAS constitutes a compartment through which vessels branch and connect before reaching the subdermal level [23]. These vessels supply the skin with blood, whereas the SMAS itself is less vascularized [28].

Overall, the anatomy of the SMAS is of high relevance to rejuvenation surgery. The goals of rhytidectomy in a functional-anatomic sense are elevation, mobilization, and repositioning of facial soft tissues. Based upon the anatomic relationships of the SMAS, a variety of face-lifting techniques have been developed in the past decades: sub-SMAS [20], extended sub-SMAS [17], sub-periosteal [22], deep-plane [10], composite [11], multiplane [5,26] rhytidectomy, and several more, discussion of which is beyond the scope of this article. Nevertheless, the zone which provides the greatest challenge for facial rejuvenation is the nasolabial fold [17,21]. This region is anatomically characterized by the abrupt change between type 1 and type 2 of SMAS architecture with the nasolabial fold as a line of juncture of two skin territories [28]. Thus type 1 of SMAS architecture is located lateral to the nasolabial fold with relatively small fibrous septa, while medially the SMAS consists of a dense collagen–muscle–fiber meshwork (type 2). These two architectures have distinct biomechanical properties. The type 2 architecture confers a firm connection of the facial muscles to the skin of the lips, and thus directly influences the complex movements of the mouth. In contrast, the type 1 architecture lateral to the nasolabial fold is more susceptible to the aging process.

Summary

A better understanding of facial anatomy and histology may facilitate rejuvenation of the facial tissue. Since different facial regions show specific morphological characteristics, region-specific interventions may be necessary. It means we may have to use different rejuvenation techniques anterior and posterior to the nasolabial fold to have a long-lasting result without injury to such important structures as the facial nerve.

Analysis of patients' age and gender may shed light on the possible differences in flaccidity of the integument.

Acknowledgements We thank Anita Agbedor and Petra Ibold for their technical assistance, and Wolfgang Graulich, who drew Fig. 1 and 11. This work was supported by grants of the RWTH Aachen (START program).

References

1. Adamson JE, Toksu AE: Progress in rhytidectomy by platysma SMAS rotation and elevation. *Plast Reconstr Surg* **68:**23–33, 1981
2. Axer H, Keyserlingk DGv, Prescher A: Collagen fibers in linea alba and rectus sheaths: I. General scheme and morphological aspects. *J Surg Res* **96:**127–134, 2001
3. Axer H, Keyserlingk DGv, Prescher A: Collagen fibers in linea alba and rectus sheaths: II. Variability and biomechanical aspects. *J Surg Res* **96:**239–245, 2001
4. Baker DC, Conley J: Avoiding facial nerve injuries in rhytidectomy. Anatomical variations and pitfalls. *Plast Reconstr Surg* **64:**781–795, 1979
5. Baker SR: Triplane rhytidectomy. *Arch Otolaryngol Head Neck Surg* **123:**1167–1172, 1997
6. Campiglio GL, Candiani P: Anatomical study on the temporal fascial layers and their relationship with the facial nerve. *Aesth Plast Surg* **21:**69–74, 1997
7. Fuleihan NS: The nasolabial fold and the SMAS. *Plast Reconstr Surg* **94:**1091–1093, 1994
8. Gosain AK, Yousif NJ, Madiedo G, Larson DL, Matloub HS, Sanger JR: Surgical anatomy of the SMAS: a reinvestigation. *Plast Reconstr Surg* **92:**1254–1263, 1993
9. Gray H: *Anatomy of the human body, 25th ed.* Lea & Febiger, Philadelphia, p 352, 1949
10. Hamra ST: The deep-plane rhytidectomy. *Plast Reconstr Surg* **86:**53–61, 1990
11. Hamra ST: Composite rhytidectomy. *Plast Reconstr Surg* **90:**1–13, 1992
12. Har-Shai Y, Bodner SR, Egozy-Golan D, Lindenbaum ES, Ben-Izhak O, Mitz V, Hirshowitz B: Mechanical properties and microstructure of the superficial musculoaponeurotic system. *Plast Reconstr Surg* **98:**59–70, 1996
13. Har-Shai Y, Bodner SR, Egozy-Golan D, Lindenbaum ES, Ben-Izhak O, Mitz V, Hirshowitz B: Viscoelastic properties of the superficial musculoaponeurotic system (SMAS): a microscopic and mechanical study. *Aesth Plast Surg* **21:**219–224, 1997
14. Hönig JF: Concepts of face-lifting. State of the art. *Mund Kiefer GesichtsChir* **1**Suppl 1**:**S21–S26, 1997
15. Jost G, Levet Y: Parotid fascia and face lifting: a critical evaluation of the SMAS concept. *Plast Reconstr Surg* **74:**42–51, 1984
16. Junqueira LCU, Bignolas G, Brentani RR: Picrosirius: Staining plus polarization microscopy, a specific

method for collagen detection in tissue sections. *Histochem J* **11:**447–455, 1979
17. Mendelson BC: Correction of the nasolabial fold: Extended SMAS dissection with periosteal fixation. *Plast Reconstr Surg* **89:**822–833, 1992
18. Mitz V, Peyronie M: The superficial musculo-aponeurotic system (SMAS) in the parotid and cheek area. *Plast Reconstr Surg* **58:**80–88, 1976
19. Moss CJ, Mendelson BC, Taylor GI: Surgical anatomy of the ligamentous attachments in the temple and periorbital regions. *Plast Reconstr Surg* **105:**1475–1490, 2000
20. Owsley JQ: SMAS–platysma face lift. *Plast Reconstr Surg* **71:**573–576, 1983
21. Pensler JM, Ward JW, Parry SW: The superficial musculoaponeurotic system in the upper lip: An anatomic study in cadavers. *Plast Reconstr Surg* **75:**488–494, 1985
22. Psillakis JM, Rumley TO, Camargos A: Subperiosteal approach as an improved concept for correction of the aging face. *Plast Reconstr Surg* **82:**383–394, 1988
23. Schuster RH, Gamble WB, Hamra ST, Manson PN: A comparison of flap vascular anatomy in three rhytidectomy techniques. *Plast Reconstr Surg* **95:**683–690, 1995
24. Stuzin JM, Baker TJ, Gordon HL: The relationship of the superficial and deep facial fascias: relevance to rhytidectomy and aging. *Plast Reconstr Surg* **89:**441–449, 1992
25. Stuzin JM, Wagstrom L, Kawamoto HK, Wolfe SA: Anatomy of the frontal branch of the facial nerve: the significance of the temporal fat pad. *Plast Reconstr Surg* **83:**265–271, 1989
26. Teimourian B, Delia S, Wahrman A: The multiplane face lift. *Plast Reconstr Surg* **93:**78–85, 1994
27. Thaller SR, Kim S, Patterson H, Wildman M, Daniller A: The submuscular aponeurotic system (SMAS): a histologic and comparative anatomy evaluation. *Plast Reconstr Surg* **86:**690–696, 1990
28. Whetzel TP, Stevenson TR: The contribution of the SMAS to the blood supply in the lateral face lift flap. *Plast Reconstr Surg* **100:**1011–1018, 1997
29. Yousif NJ, Gosain A, Matloub HS, Sanger JR, Madiedo G, Larson DL: The nasolabial fold: An anatomic and histologic reappraisal. *Plast Reconstr Surg* **93:**60–69, 1994