ORIGINAL ARTICLE

Surgical Anatomy of the Face

Implications for Modern Face-lift Techniques

Holger G. Gassner, MD; Amir Rafii, MD; Alison Young, MD, PhD; Craig Murakami, MD; Kris S. Moe, MD; Wayne F. Larrabee Jr, MD

Objective: To delineate the anatomic architecture of the melolabial fold with surrounding structures and to elucidate potential implications for face-lift techniques.

Methods: A total of 100 facial halves (from 50 cadaveric heads) were studied, including gross and microscopic dissection and histologic findings. Laboratory findings were correlated with intraoperative findings in more than 150 deep-plane face-lift dissections (300 facial halves) performed during the study period.

Results: In contrast to previous reports, the superficial musculoaponeurotic system (SMAS) was not found to form an investing layer in the midface. The SMAS, zygomatici muscles, and levator labii superioris alaeque nasi were found to be located in corresponding anatomic layers and to form a functional unit. Additional findings of the present study include the description of 3 structurally different portions of the melolabial fold, of an anatomic space below the levator labii superioris alaeque nasi (sublevator space), and of extensions of the buccal fat pad into the sublevator space and the middle third of the melolabial fold.

Conclusions: The findings of the present study may contribute to augment our understanding of the complex anatomy of the midface and melolabial fold. Potential implications for modern face-lift techniques are discussed.

Arch Facial Plast Surg. 2008;10(1):9-19

Author Affiliations: The Larrabee Center for Facial Plastic Surgery, Seattle, Washington (Drs Gassner, Rafii, and Larrabee); Division of Facial Plastic Surgery, Department of Otorhinolaryngology (Drs Gassner, Rafii, and Murakami), and Department of Dermatology (Dr Young), Virginia Mason Hospital, Seattle; and Division of Facial Plastic Surgery, Department of Otorhinolaryngology (Drs Gassner and Moe), University of Washington, Seattle. Dr Gassner is now with the Division of Facial Plastic Surgery, Department of Otorhinolaryngology, University of Regensburg, Regensburg, Germany.

THE EVOLUTION OF COMplex face-lift techniques has been stimulated by an increasingly more detailed understanding of the layered anatomic architecture of the face.[1,2] A milestone in the development of modern face-lift techniques was the description of the superficial musculoaponeurotic system (SMAS) by Mitz and Peyronie[3] and the introduction of the sub-SMAS dissection by Skoog.[4] These modifications have resulted in substantial long-term improvements of the neck and jawline. More advanced techniques followed with the purpose of better addressing the melolabial fold. Most noteworthy have been the contributions of Hamra[5] as well as those of Baker[6] and Kamer,[7] who described variations of deep-plane dissections.[6-8] However, despite the expert execution of the most sophisticated techniques, initial improvement of the melolabial fold has not been observed to consistently persist long term.[9-11] Our current understanding of the anatomy of the midface and especially the melolabial fold is insufficient to explain the resistance of these areas to correction and to provide for a more rational approach to their surgical rejuvenation. Of course, our efforts at improving the nasolabial fold should be measured because complete effacement of this fold would remove this aesthetically important landmark, which delineates the transition between the aesthetic units of the cheek and mouth.[12]

The SMAS is the key element most face-lift techniques have been designed to reposition and suspend. Although the SMAS is a clearly identifiable structure lateral to the zygomaticus major muscle, its presence and structure are not as well understood medial to this muscle. Hence, its role in deep-plane face-lift dissection has not been exactly defined. Some authors[3] have described the SMAS as an investing layer that envelopes the musculature of the midface; others[13,14] have described it as a separate layer that is located superficial to the mimetic muscles and extends into the melolabial fold. Most studies present histologic sections of limited aspects of the midface or of the melolabial fold depicting some fibrous strands, which are designated to be the SMAS. To our knowledge, no study has been published that conclusively demonstrates the SMAS to be a continuous layer spanning from the mandible or parotid fascia into the midface and melolabial fold.

As is the case for the SMAS, our knowledge of the structure of the melolabial fold

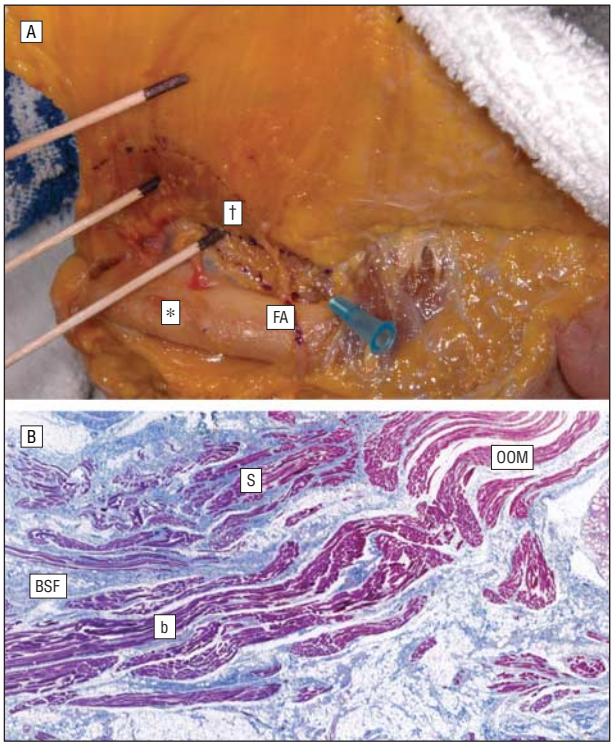

Figure 1. Platysma and superficial musculoaponeurotic system (SMAS) dissected off the mandible. A, From top to bottom, the 3 wooden indicators point to the platysma, the SMAS (transitioning to orbicularis oris muscle), and the inferior border of SMAS-buccinator fusion. The needle is inserted through the buccinator muscle. Asterisk, the transected mandibulocutaneous ligament; dagger, fibers of zygomaticus major muscle radiating toward the modiolus; FA, facial artery. B, Histologic cross section of the buccinator-SMAS fusion. The "b" indicates the buccinator muscle; S, SMAS; BSF, the zone of fusion between buccinator muscle and the SMAS (note that the layered architecture of these 2 muscles is preserved); and OOM, orbicularis oris muscle (hematoxylin-eosin, original magnification ×16).

is also incomplete. Despite the substantial body of literature that has emerged since Rubin's[15] landmark article, many important questions regarding its microanatomy and relationship with surrounding structures remain elusive. These include the structure and position of the fat compartments forming the melolabial bulge. Stuzin et al[16] described various portions of the buccal fat, including its body and buccal extension, but to our knowledge, no extension past the facial vessels into the melolabial fold has been described. Further remaining questions include the potential relation of the melolabial fold with the SMAS, its support mechanism, and their attenuation with age.

METHODS

Fifty fresh frozen cadaveric heads (100 facial halves) were dissected using ×2.5 extended field magnifying loupes (Designs for Vision, Ronkonkoma, New York) or a Pico otologic microscope (Zeiss Inc, Thornwood, New York) at various magnifications. Observations were documented with pencil sketches, single-lens reflex macroscopic and microscopic digital photography, and standard and microscopic videography. Single-lens reflex macrophotographs were obtained using a Nikon camera (model D70s; Nikon Inc, Melville, New York), Sigma 17-70 mm 1:2.8-4.5 macrolens (Sigma Inc, Ronkonkoma, New York), and Sigma macroring light flash (model EM 140 iTTL; Sigma Inc) at the following settings: aperture F18, shutter speed 1/60 s, ISO 200, white balance flash, manual focus, and 70-mm focal length.

Microscopic photographs and video clips were obtained using an otologic microscope (model OPMI Pico; Zeiss Inc) with an attached camera (model 882 TE HDDC; Stryker Inc, Mahwah, New Jersey) and a digital recording device (model SDC Pro 2; Stryker Inc). Photographic and video documentation was intermittently reviewed between laboratory dissections to plan subsequent dissections.

Histologic sections were obtained from 5 cadaveric heads (10 facial halves) from the following locations: cross-sections through the superior, middle, and inferior thirds of the melolabial fold; horizontal and vertical sections through the buccinator-SMAS fusion; horizontal sections through the modiolus and cheek at various levels; and sections perpendicular to the mid portion of the zygomaticus major muscle. After removal of the specimen, the layered architecture of the cut surfaces was photographed for orientation and also studied using microscopic dissection techniques. The tissue sections were fixed in formalin, and paraffin embedding was performed by dehydrating the tissue blocks through ethanol and Histoclear (National Diagnostics, Atlanta, Georgia) before immersion in paraplast (Fisher Scientific, Waltham, Massachusetts). Sections of 4 µm were stained with hematoxylin-eosin and Masson trichrome stains and examined under light microscopy. Histologic photographs were taken with a Coolscan 4000 slide scanner (Nikon Inc) or photomicroscope at original magnifications ×1 and ×2.5 (Zeiss Inc).

We performed more than 150 deep-plane face-lift procedures during the study period (July 1, 2006, to June 31, 2007), and our intraoperative observations were documented in tabulated form to corroborate and verify the laboratory findings. Intraoperative observations included the presence of the parotid fascia after elevation of the SMAS, the absence of the SMAS on the deep aspect of the malar fat pad after deep-plane dissection, the effect of deep-plane dissection and SMAS repositioning on the melolabial fold, and the ease of dissection along the medial aspect of the deep plane with respect to the position of the buccinator-SMAS fusion.

The melolabial fold was marked and a 3-mm strip of skin was preserved over the melolabial fold. The facial skin was then dissected in the immediate subdermal plane and removed both medially and laterally. The underlying fat was identified and inspected. The fascial insertions of the melolabial fold were then followed along their lateral aspect and their relations with the fat pads of the cheek, the levator labii superioris alaeque nasi muscle, buccinator muscle, orbicularis oris muscle, zygomaticus major muscle, and SMAS were studied. Dissections of the subdermal (malar) fat pad were performed along its undersurface in multiple directions. The relation of the SMAS to the buccal fat pad and retromandibular space was inspected. Medial to the melolabial fold, the subdermal fat overlying the orbicularis oris and levator labii superioris alaeque nasi muscle was also removed. In the subsequent specimen, the platysma and the SMAS were elevated by inferior to superior dissection over the mandible into the midface and in a lateral to medial direction according to superficial, sub-SMAS, deep-plane, and composite face-lift techniques. The relation of the SMAS to the mandible, mandibulocutaneous ligament, infraorbital, mental and facial nerves, facial vessels, and perioral, buccinator, and zygomatici muscles was studied. We also studied the relation of the superomedial edge of the SMAS to the soft tissues of the midface. Subsequently, we performed dissections to study specific structures and relations, including the sublevator space and fat pad, the buccinator-SMAS fusion, the superomedial edge of the SMAS, the transition of the temporoparietal fascia over the zygoma into the SMAS and into the zygomaticus major

muscle, and the layered structure of the transition from the buccinator-SMAS fusion to the modiolus.

RESULTS

PLATYSMA AND SMAS

When the platysma is dissected, its medial edges can be distinctly identified because they leave a median dehiscence of variable width in the midline. The superior edge of this dehiscence borders on the inferior edge of the mentalis muscle. When the medial edge of the platysma is followed in a superolateral direction over the mandible, it continues as the SMAS into the face. It becomes obvious that the SMAS and platysma represent an anatomically homogeneous unit that maintains its muscular consistency and direction of fibers as it crosses the mandible. The mandibulocutaneous ligament fixates the inferomedial aspect of the SMAS and is found to lie with little variation 40 mm from the midline and 6 mm above the inferior edge on the ramus of the mandible. Following the SMAS further superiorly, it forms a zone of fusion with the buccinator muscle (**Figure 1**A). The posterior edge of this zone is approximately 4 mm anterior to the point where the facial artery courses over the mandible, and its superior edge remains inferolateral to the body of the zygomaticus major muscle. With appropriate countertraction, this zone of fusion delineates a plane that separates with sharp dissection. Histologically, this zone maintains its layered architecture, and the SMAS and the buccinator muscle remain separately identifiable (Figure 1B). This plane can be further followed anteriorly to the modiolus where the zygomaticus major muscle, SMAS, and buccinator muscle merge with the orbicularis oris muscle. This is the only point where the SMAS forms a continuous muscular structure with the zygomaticus major muscle. Superolateral to the modiolus, a soft tissue gap separates the zygomaticus major muscle and the SMAS. When the anterior edge of the SMAS is followed superolaterally, it changes from a purely muscular to a more fibrous consistency as it attaches to the zygomatic arch.

Microscopic and cross-sectional histologic study of its medial aspects show that the SMAS does not split around or invest the zygomaticus muscle group (**Figure 2**A). It rather attenuates lateral to the zygomaticus major in a plane between the malar (subcutaneous) and the buccal fat pads. This plane dissects bluntly and frequently harbors a fine fascia that spans from the SMAS to the body of the zygomaticus major muscle.

No ligamentous or fascial attachments that could transmit tension connect the SMAS with the middle or upper third of the melolabial fold. When the massetericocutaneous and platysmoauricular ligaments are adequately freed up, lateral tension on the SMAS is transmitted only to the buccinator muscle, modiolus, and orbicularis oris muscle.

TEMPOROPARIETAL FASCIA

In the present study, the temporoparietal fascia was consistently found to form a tight fibrous fusion with the inferior extensions of the underlying superficial and deep layers of the deep temporal fascia at their insertion into the zygomatic arch. Release of the SMAS and the temporoparietal fascia as 1 continuous sheet was possible but required sharp retrograde dissection of the SMAS over the zygoma. Retrograde dissection of the origin of the zygomaticus major muscle also led into this subgaleal plane. This finding suggests that these 3 muscle groups (temporoparietal fascia, zygomaticus major muscle, and SMAS) lay within corresponding anatomic layers.

The common description of the SMAS and temporoparietal fascia as a homogeneous, continuous layer that may

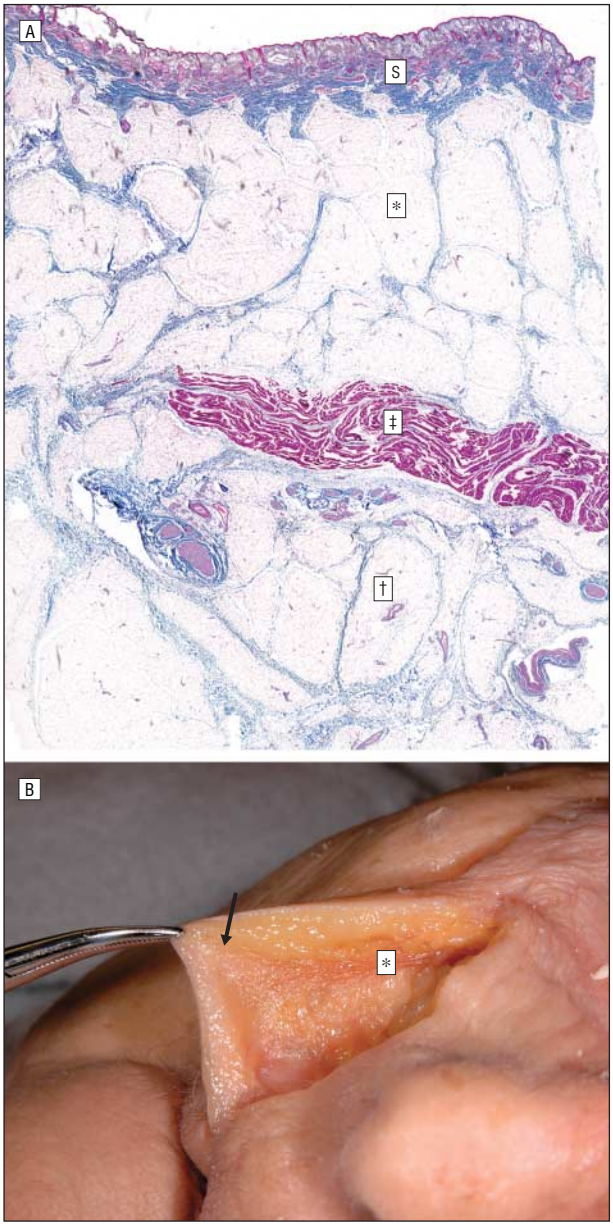

Figure 2. A cross section through the cheek at the level of zygomaticus major muscle has been performed. A, The asterisk indicates a malar fat pad; dagger, a buccal fat pad; double dagger, a histologic cross section through zygomaticus major muscle; S, cheek skin (note the absence of a structure that would represent the superficial musculoaponeurotic system as a layer investing the zygomaticus muscle or as a layer superficial to that muscle) (hematoxylin-eosin, original magnification ×10). B, Asterisk, the cross section through the zygomaticus major muscle; arrow, fascial extension into the dermis responsible for dynamic cheek dimples.

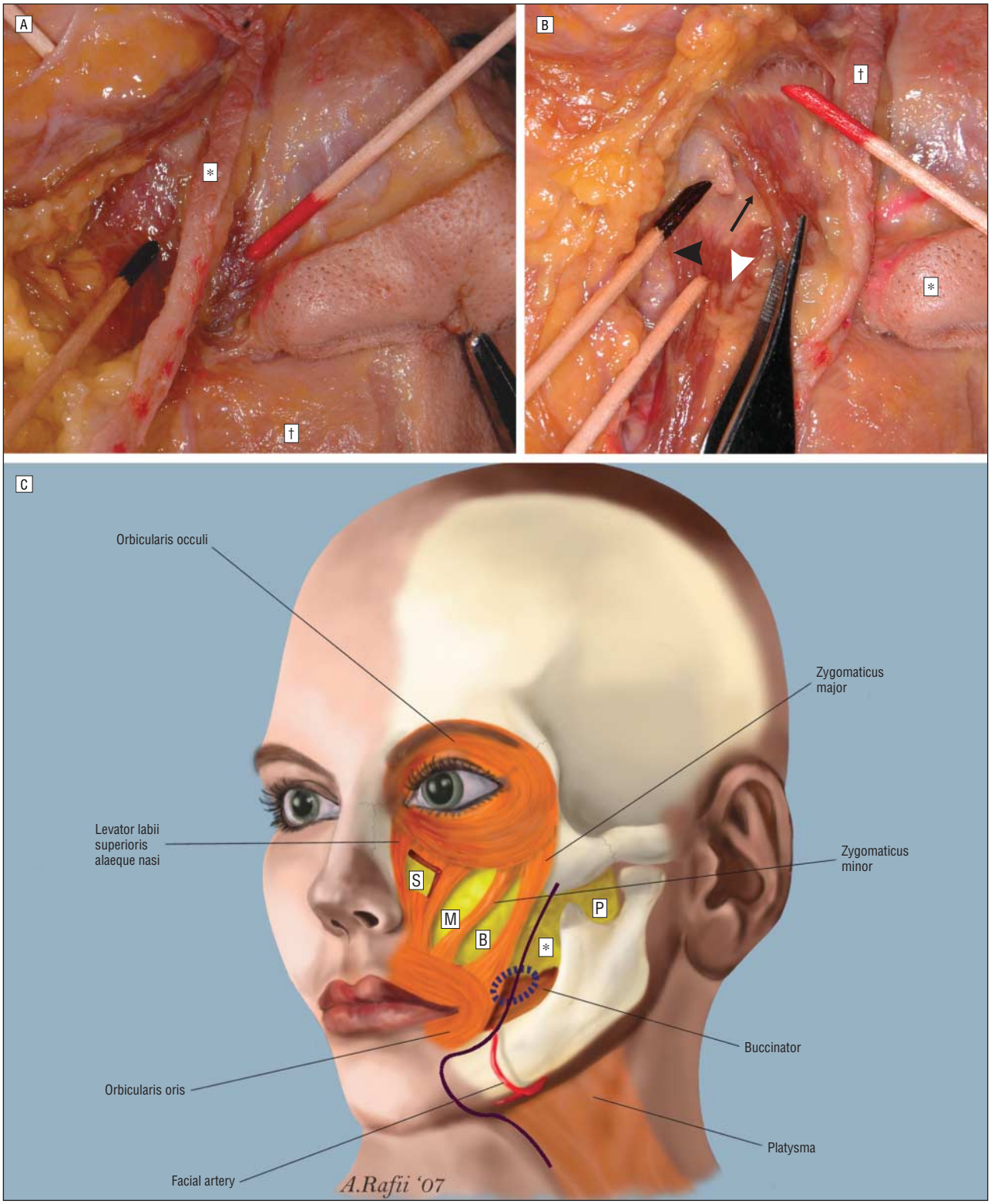

Figure 3. The dissection of the melolabial fold. A, Skin and subcutaneous fat medial and lateral to melolabial fold removed. The black wooden indicator points to the levator labii superioris alaeque nasi muscle; red wooden indicator, medial insertions of levator labii superioris alaeque nasi muscle into the frontal process of the maxilla; uncolored wooden indicator, the Lockwood ligament. Asterisk, the strip of skin preserved over melolabial fold; dagger, the orbicularis oris muscle. B, Sublevator space after removal of sublevator extension of buccal fat pad. The arrow points into the sublevator space. The forceps holds the levator labii superioris alaeque nasi muscle, which forms the roof of the sublevator space. The red wooden indicator points to the origin of the levator labii superioris alaeque nasi muscle; black wooden indicator, the infraorbital nerve; uncolored wooden indicator, the levator anguli oris muscle. Asterisk, the right nasal ala; dagger, the strip of skin preserved over the melolabial fold. The black arrowhead indicates the position of a removed buccal extension of buccal fat pad; white arrowhead, position of a removed melolabial extension of buccal fat pad. C, Schematic depiction of the deep fat pads of the face. Pertinent mimetic muscles are depicted for orientation. The "S" indicates the sublevator extension of buccal fat pad located within the sublevator space; "M," the melolabial extension of buccal fat pad inferolateral to levator labii superioris alaeque nasi muscle; "B," the buccal extension of buccal fat pad is located lateral to the facial vessels; "P," the pterygoid extension of buccal fat pad. The asterisk indicates the body of buccal fat pad. A solid line indicates lateral border of the SMAS, and dashed line, the buccinator–superficial musculoaponeurotic system fusion.

be identified in a plane superficial to the periosteal attachments of the deep temporal fasciae could not be reproduced. The transition of the SMAS into the temporoparietal fascia was rather found to be incorporated into the bony attachments of the deep temporal fasciae into the zygoma.

ZYGOMATICUS MAJOR MUSCLE

The zygomaticus major muscle spans from the anterior aspect of the zygomaticotemporal suture line to the orbicularis oris muscle at the oral commissure. At its origin, the zygomaticus major muscle overlaps the anteriormost aspect of the origin of the masseter muscle. Distally, the zygomaticus major muscle fuses with the orbicularis oris muscle, the SMAS, and the buccinator muscle to form the modiolus. Proximal to this fusion, fascial insertions were observed in some specimens to connect to the overlying skin. These fascial bands may serve as an explanation for the presence of dynamic cheek dimples in some individuals (Figure 2B). Lateral and medial to the zygomaticus major muscle, a plane of dissection could be easily entered. This plane divides the malar from the buccal fat and frequently harbors a fine fascial layer, connecting this muscle with the SMAS inferiorly and the zygomaticus minor muscle superiorly. Thus, these 3 muscles were observed to be located in a corresponding anatomic layer.

ZYGOMATICUS MINOR MUSCLE

The zygomaticus minor muscle may represent a direct lateral extension of the levator labii superioris alaeque nasi muscle, or it may be separated by a soft tissue gap. When this soft tissue gap exists, it is frequently spanned by a very fine fascial layer that creates a division between the subdermal (malar) and the buccal fat compartment. The zygomaticus minor muscle inserts into the inferolateral edge of the levator labii superioris alaeque nasi muscle. This insertion reached in some, but not all, specimens of the orbicularis oris muscle.

ORBICULARIS ORIS MUSCLE

The orbicularis oris muscle fuses laterally at the modiolus with the SMAS, zygomaticus major, and buccinator muscle. The modiolus forms a tendinous attachment for this lateral muscle group and seems to transmit superolateral traction to the oral commissure, thus playing an important role in the smiling mechanism. The superficial, peripheral aspects of the orbicularis oris muscle were found to be in a layer corresponding with the SMAS and the zygomaticus group of muscles. Its deeper aspects were found to interdigitate with the buccinator muscle (Figure 1A and B).

LEVATOR LABII SUPERIORIS ALAEQUE NASI MUSCLE

The inferolateral aspect of the levator labii superioris alaeque nasi muscle harbors part of the insertion of the zygomaticus minor muscle. In some specimens, both muscles were in anatomic continuity. Superolaterally, the levator labii superioris alaeque nasi muscle originates obliquely from the infraorbital rim. Medially, the dermal fascial extensions of the melolabial fold join the levator labii superioris alaeque nasi muscle and insert along the frontal process of the maxilla (**Figure 3**A). Both the medial and superolateral edges of the levator labii superioris alaeque nasi muscle are hence tethered to the bony skeleton. Medially, the levator labii superioris alaeque nasi muscle continues past its insertion in the bone to fuse with the nasal musculature. Through its triangular origin from the bone, the levator labii superioris alaeque nasi muscle confines a distinct 3-dimensional space on its deep aspect, which will be referred to hereinafter as the sublevator space.

SUBLEVATOR SPACE

The roof of the sublevator space is formed by the levator labii superioris alaeque nasi muscle and its floor by the facial surface of the maxilla surrounding the infraorbital foramen and by the origin of the levator anguli oris muscle over the superior aspect of the canine fossa. Medially, the sublevator space is confined by the insertion of the levator labii superioris alaeque nasi muscle into the frontal process of maxilla, and laterally, by the origin of the levator labii superioris alaeque nasi muscle along the infraorbital rim (Figure 3B). The sublevator space is not potential or collapsed but rather kept open by a fat pad of substantial volume. Hereinafter, this fat pad will be referred to as the sublevator extension of the buccal fat pad.

SUBLEVATOR AND MELOLABIAL EXTENSIONS OF THE BUCCAL FAT PAD

The sublevator extension of the buccal fat pad surrounds the infraorbital foramen, fills the sublevator space, and prolapses inferiorly and laterally (Figure 3B). The inferiorly prolapsing portion spills past the edge of the levator labii superioris alaeque nasi muscle to cover the origin of the levator anguli oris muscle over the canine fossa. Hereinafter, this portion will be referred to as the melolabial extension of the buccal fat pad (Figure 3C). It is located medial to the facial vessels, fills the deep aspect of the middle third of the melolabial fold, and rests on the levator anguli oris muscle, the periosteum of the face of the maxilla (including canine fossa), and the buccinator muscle. The melolabial extension of the buccal fat pad contributes substantially to the appearance of the melolabial fold and the volume of the melolabial bulge (**Figure 4**). A distinct plane separates the melolabial extension of the buccal fat pad from the overlying subdermal (or malar) fat (**Figure 5**A). This plane frequently harbors a fine but distinct fascial layer that spans the gap between the levator labii superioris alaeque nasi and the zygomaticus major muscles. Within the middle third of the melolabial fold, the thickness of the melolabial extension of the buccal fat pad decreases, whereas superiorly to inferiorly the thickness of the subdermal (malar) fat increases. Biomechanically, these 2 fat pads seem to articulate and compliment each other's shape and volume as they form the melolabial bulge, but they have distinctly different colors and textures.

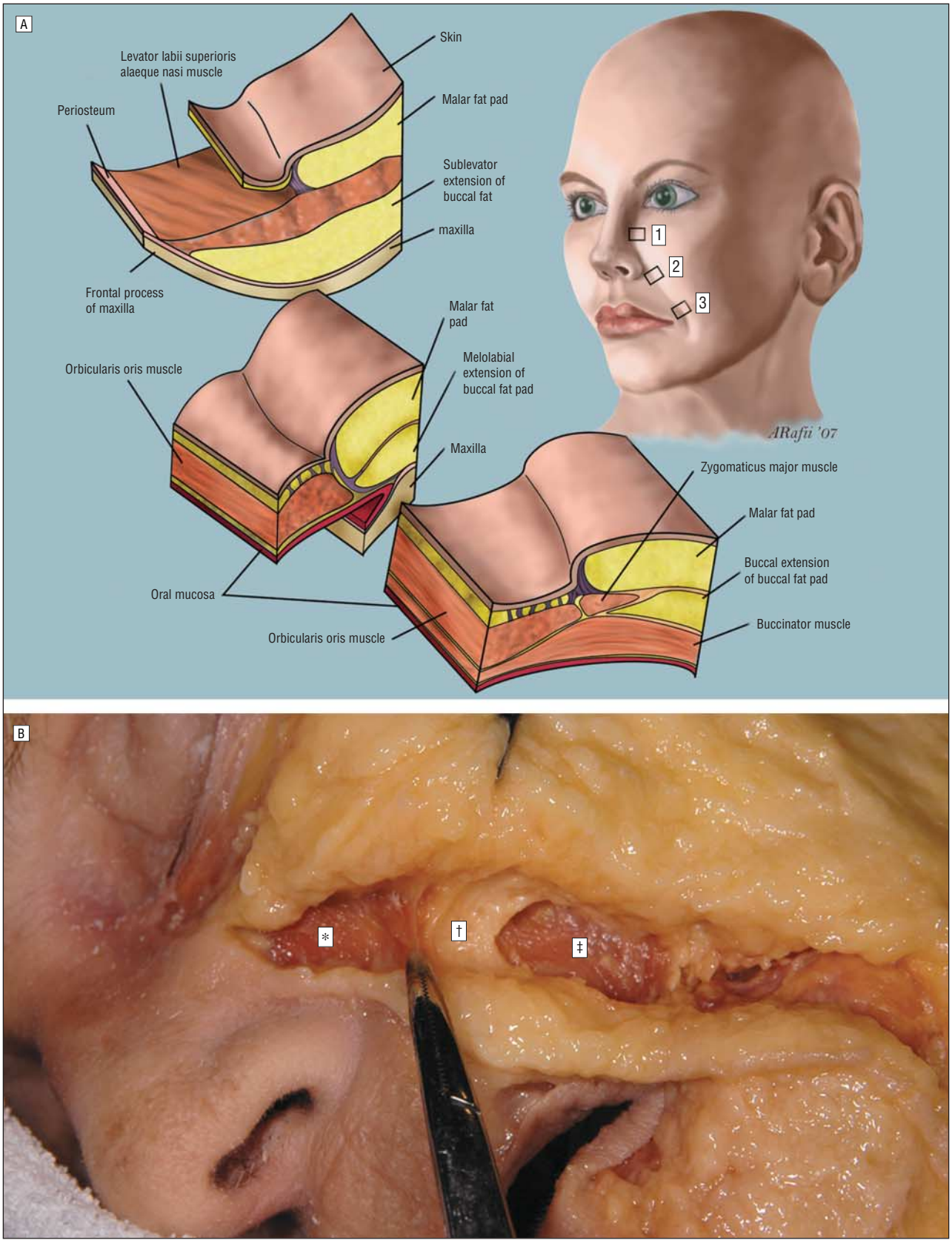

Figure 4. The melolabial fold. A, Division of the melolabial fold into horizontal thirds, delineated by the underlying structures: the levator labii superioris alaeque nasi muscle (upper third), orbicularis oris muscle (lower third), and soft tissue gap between these muscles (middle third). B, The melolabial fold is divided into 3 horizontal thirds, delineated by the underlying structures. Asterisk, the levator labii superioris alaeque nasi muscle; dagger, the subzygomatic extension of sublevator fat pad; double dagger, the orbicularis oris muscle.

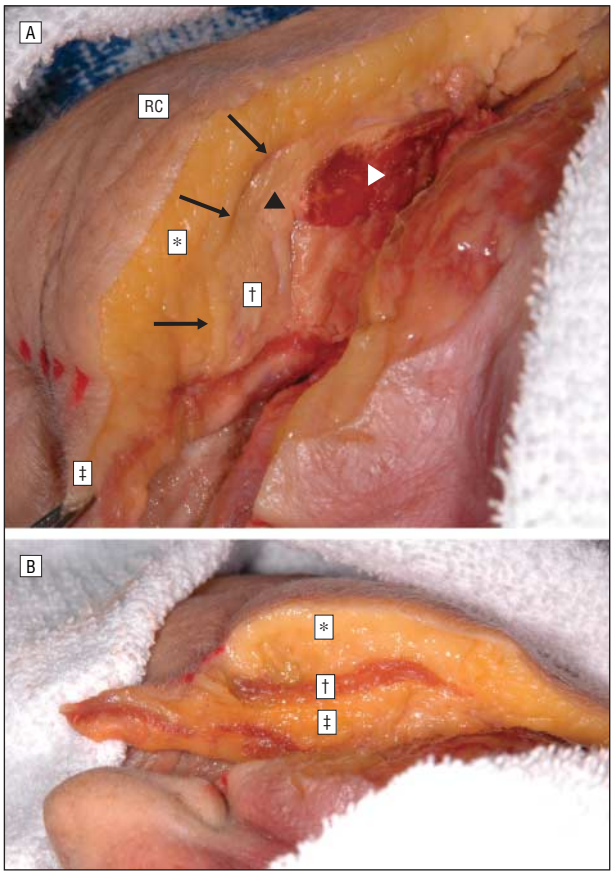

Figure 5. The photograph shows a gross cross section. A, Cross section through the middle third of the melolabial fold. Arrows indicate transition between the malar fat pad (asterisk) and the melolabial (dagger) and buccal (white arrowhead) extension of the buccal fat pad. The black arrowhead indicates the masseter muscle. Double dagger, the thin layer of subcutaneous fat over the orbicularis oris muscle. B, Cross section through cheek along the zygomaticus major muscle (dagger). The plane of this muscle divides the overlying malar fat pad (asterisk) from the underlying buccal extension of the buccal fat pad (double dagger), which acts as a gliding pad for this muscle.

Lateral to the level of the facial vessels, the sublevator and melolabial extensions of the buccal fat are confluent with the buccal extension of the buccal fat pad, which is separated from the overlying malar fat pad by the zygomatici muscles (Figure 5B). Thus, the buccal extension of the buccal fat pad can act as a gliding pad for the zygomatici muscles. More laterally, the buccal extension of the buccal fat pad is continuous with the body of the buccal fat pad.

Both the melolabial extension of the buccal fat pad and the overlying malar fat pad are confined medially by fascial insertions from the melolabial fold into the dermis. These fascial extensions follow the medial edge of both fat pads and extend toward the deep aspect of the melolabial extension of the buccal fat pad, thus giving the medial aspect of these fat pads structural resilience. Hence, these fascial insertions support the fat pads like a hammock, resisting their tendency to prolapse inferomedially. These fascial extensions have no insertions into the bone of the face of the maxilla. The condensation of the SMAS with the buccinator muscle (buccinator-SMAS fusion) confines the melolabial extension of the buccal fat pad inferiorly.

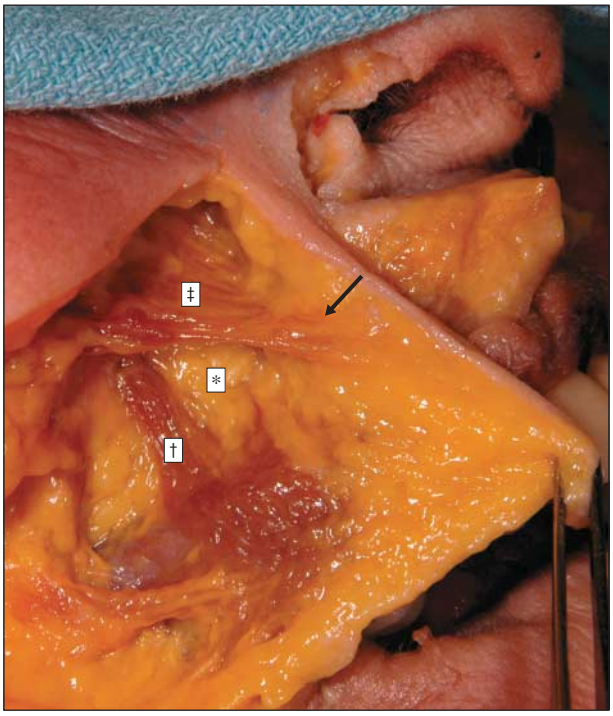

Figure 6. Fascial bands from the levator labii superioris alaeque nasi muscle insert into the upper third of the melolabial fold. Sublevator extension of the buccal fat pad (asterisk) fills the sublevator space. Dagger, the levator anguli oris muscle. Double dagger, the levator labii superioris alaeque nasi muscle, which is the roof of the sublevator space. The arrow points to the insertion of the levator labii alaeque nasi.

MELOLABIAL FOLD

The melolabial fold (and medially adjacent melolabial bulge) was found to be divided into 3 structurally different horizontal thirds, which are separated by distinct anatomic landmarks. These landmarks are as follows: the fusion of the uppermost dermal attachments of the melolabial fold with the origin of the levator labii superioris alaeque nasi muscle, the inferior edge of the levator labii superioris alaeque nasi muscle (transition of upper to middle third), the superior edge of the orbicularis oris muscle (transition of middle to lower third), and the fusion of the dermal fascial attachments of the melolabial fold with the inferior aspect of the orbicularis oris muscle (inferior apex) (Figure 4).

The dermal fascial attachments of the superior third of the melolabial fold, starting at the (superior) apex of the fold, insert into the surface of the levator labii superioris alaeque nasi muscle (**Figure 6**). These insertions form a line, which divides the levator labii superioris alaeque nasi muscle into a narrower medial and a larger lateral portion.

The longitudinal insertion of the melolabial fold into the levator labii superioris alaeque nasi muscle explains the characteristic mobility of the melolabial fold in this area: the levator labii superioris alaeque nasi muscle and underlying sublevator extension of the buccal fat pad serve as a gliding pad for the insertion of the melolabial fold and allow for moderate excursions in both the horizontal (medial to lateral) and vertical (superior to inferior) planes. Following the levator labii superioris alaeque nasi

muscle inferiorly, the lateral edge of this muscle courses medially and inserts into the orbicularis oris muscle. This insertion is medial to the melolabial fold. In other words, the medial portion of the levator labii superioris alaeque nasi muscle harbors the insertion of the levator labii superioris alaeque nasi muscle into the orbicularis oris muscle. The dermal fascial attachments of the melolabial fold course lateral to this insertion and cross the gap between the inferolateral edge of the levator labii superioris alaeque nasi muscle and the superolateral aspect of the orbicularis oris muscle. This gap is filled with fatty tissue and represents the middle third of the melolabial fold. Here, the bulge lateral to the fold is formed by the malar fat and the melolabial extension of the buccal fat pad. Inferiorly, the insertion of the fascial dermal attachments of the melolabial fold along the orbicularis oris muscle (which includes the fusion of the orbicularis oris muscle and the zygomaticus major muscle) marks the inferior third of the melolabial fold. The dermal fascial attachments of the melolabial fold form a relatively fine band in the upper third of the melolabial fold and become wider over the medial aspect of the middle and inferior third over the fold, encompassing the subcutaneous tissues overlying the orbicularis oris muscle.

COMMENT

PLATYSMA AND SMAS

Ever since Mitz and Peyronie[3] wrote their classic description of the SMAS, its anatomic relation to the parotid fascia, the temporoparietal fascia, and the muscles of the midface and melolabial fold have been debated. The excellent histologic study by Gosain et al[17] shed light on some of these questions because it showed the parotid fascia to be a separate layer. Gosain et al[17] also claimed that the SMAS is not in anatomic continuity with the temporoparietal fascia, a statement that challenged previous descriptions, including those of Mitz and Peyronie.[3] Our findings support the conclusions of Gosain et al.[17] The SMAS attenuates superiorly as it courses over the zygomatic arch. Its fascial extensions form insertions into the zygomatic arch, which, when released, allow elevation of the SMAS and temporoparietal fascia in 1 layer. The notion that both the SMAS and the temporoparietal fascia are situated in corresponding anatomic layers and have lost their anatomic continuity as they fused to the zygomatic arch seems to be logical.

The substantial variability in descriptions of the anatomy of the SMAS in the midface may be explained by propagation of early, inconcise descriptions in the literature. Gray[18] stated that "The superficial fascia of the head invests the facial muscles." Mitz and Peyronie[3] stated that "[The SMAS] is also still present anteriorly, superficial to the facial muscles, as shown by our dissections and histologic studies. However, the SMAS becomes thin and discontinuous in the cheek area." The notion that the SMAS splits and invests the facial muscles is widely reported, yet conclusive scientific evidence demonstrating such a finding is lacking.[7,14,17,19] To our knowledge, no histologic image has been shown in the literature to demonstrate the SMAS as a distinct layer spanning from the parotid or mandible to the melolabial fold. To better understand the potential relation of the SMAS with the mimetic muscles of the midface, certain developmental and functional aspects should be considered. Functionally, the SMAS has been described as an aponeurotic structure with muscular elements. Ever since the classic dissertation by Jost and Levet[20] was published, it has been widely accepted that the SMAS in the lower face represents an extension of the platysma across the mandible. As noted by Gray,[18] the platysma (and hence the SMAS) should be classified as a facial muscle. It is innervated by the facial nerve and has distinct bony insertions at the mandibulocutaneous ligament and the zygoma. Anatomically, more representative nomenclature would divide the platysma into a cervical portion (the platysma proper) and a facial portion (the SMAS), divided by the rim of the mandible. Because the term *SMAS* is well established, herein we use it to describe the supramandibular, facial portion of the platysma.

In the present study, superficial and deep dissections of the SMAS in various directions all led to the conclusion that the SMAS forms a sheet with the zygomatici and levator labii superioris alaeque nasi muscles. The gaps between these muscles were frequently connected by a fine fascia. Our findings are not consistent with reports that the SMAS represents an investing layer enveloping the mimetic muscles of the midface or a layer superficial to these muscles. Other than the proper fascia of these facial muscles, no fascial structure to split around the muscles of the midface, or superficial to them, was identified. We found that the SMAS simply ends lateral to the zygomaticus major muscle, sometimes connected to this muscle by a fine fascia.

Its presumed different embryologic origin has been cited to distinguish the SMAS from the superficial group of mimetic musculature. Herein, no attempt will be made to elucidate the ontogeny of the facial muscles based on their phylogeny, yet some important developmental aspects will be discussed because they may serve as an explanation for the findings of the present study.

The notion has arisen from some observational studies that the sphincteric muscles around the mouth and eye (ie, the orbicularis oris and orbicularis oculi muscles) derive from the sphincter colli muscle, yet other studies do not support this notion.[21-23] The conclusion that the remainder of the superficial facial musculature is derived from the platysma is better established. As elegantly illustrated by Gasser[21] and confirmed by Leperchey,[23] during development, common premuscle condensations termed *laminae* develop into the superficial mimetic muscles. For instance, the zygomatici and levator labii superioris alaeque nasi muscles develop from the infraorbital lamina, and the platysma is derived from the cervical lamina. These 2 laminae are confluent in the 26-mm fetus, suggesting a very close developmental relationship of these 2 muscle groups.[21,23] Phylogenetic aspects also support the notion that the SMAS, the zygomaticus, and the levator labii superioris alaeque nasi group may share a common developmental origin. In certain older primate species, the zygomaticus major muscle is in anatomic continuity with the platysma muscle and rep-

resents a thickened bundle of muscle fibers at the superomedial aspect of the platysma. In more recent species (eg, humans), a separation of varying degrees is observed.[24,25] In the present study, we also observed that the muscle fibers of the superomedial aspect of the SMAS radiate in the same direction as those of the zygomaticus major muscle—that is, toward the modiolus—suggesting a common origin of these 2 muscles.

Based on these observations and our interpretation of the literature, we suggest that the SMAS should be regarded as a facial muscle that does not extend into the midface but rather connects with the zygomatici and levator labii superioris alaeque nasi muscles to form a functional unit and discontinuous muscle plate with these structures. The fine connecting fascia occasionally observed in the gaps between these muscles may indicate the location of a (phylogenetically) complete common precursor of these muscles. Medially, the levator labii superioris alaeque nasi was observed to be continuous with the nasal musculature, a finding that may have implications for our understanding of the SMAS of the nose.

There are muscles of the superficial mimetic group that doubtlessly occupy layers different from that of the SMAS, zygomatici, and levator labii superioris alaeque nasi muscles. The peripheral aspects of the orbicularis oculi muscle assume a more superficial location, and a portion of the peripheral aspect of the orbicularis oris muscle assumes a deeper position and communicates with the buccinator muscle. This observation may support the notion that these 2 sphincteric muscles may have developed from a different precursor (the sphincter colli muscle) than the superficial midfacial muscles.

To our knowledge, the presence of a zone of fusion observed between the SMAS and the buccinator muscle is another finding that has not been reported previously. It must be stressed that, when inspected histologically, this zone maintains a layered architecture with both muscles identified separately. When this zone is followed medially, it fuses with the orbicularis oris and zygomaticus major muscle to form the modiolus. Within the medial aspect of this zone of fusion, the orbicularis oris muscle is in continuity with extensions of both the SMAS and the buccinator muscle. Thus, a (somewhat arbitrary) division between a superficial and a deep portion of the orbicularis oris muscle can be made. Herein, no further speculation will be undertaken regarding whether such a potential division is based on different embryonic precursors or whether it represents secondary, functional accommodations.

Our laboratory findings were also supported by intraoperative observations. The deep-plane face-lift dissection follows the superficial surface of the zygomaticus major muscle in a subcutaneous plane, deep to the malar fat pad. After transection of the zygomaticocutaneous ligament, this plane allows straightforward access to the melolabial fold because the plane between the inferior extension of the sublevator fat pad and the malar (subcutaneous) fat pad divides easily. If the SMAS was to cover or invest the mimetic muscles of the midface, the undersurface of the elevated flap should be lined by the SMAS, but we did not observe this. The observations by Hamra[26] also support the notion that the deep-plane dissection does not proceed in a sub-SMAS plane in the midface: "This prezygomaticus plane dissection was then connected to the subplatysmal dissection. . . . "

Dissection of the deep plane along the zygomaticus major muscle proceeds easily until the SMAS-buccinator fusion provides resistance more inferiorly. This zone of fusion can also be palpated with a blunt spreading instrument that proceeds in the sub-SMAS plane along the mandible and is then directed upward.

One may speculate that this zone of fusion mediates contractions of the buccinator muscle when a person is smiling and that the buccinator muscle plays an important role in facial expression. When the massetericocutaneous and platysmoauricular ligaments are adequately freed up, tension on a long SMAS flap is transmitted to the buccinator muscle, modiolus, and orbicularis oris muscle, resulting in lateralization and elevation of the melolabial fold and corner of the mouth. This mechanism may be responsible for the friendlier, more smiling appearance of the mouth after successful deep-plane face-lift surgery. No firm ligamentous or fascial attachments connect the SMAS with the middle or upper third of the melolabial fold. The lesser, but notable, superolateral elevation of these areas with tension on the SMAS seems to be indirectly transmitted by the overlying skin and mass movements of the soft tissue envelope.

MELOLABIAL FOLD

The present findings also permit the delineation of anatomically distinct portions of the melolabial fold and adjacent bulge. The superior third represents the aspect over the levator labii superioris alaeque nasi, the inferior third is situated over the orbicularis oris muscle, and the middle third is located over the soft tissue gap between the 2 muscles. Here, the fascial extensions of the fold interdigitate with the medial aspect of 2 underlying fat pads. The lack of bony anchors for the fascial bands of the middle third may represent a weak spot in the suspensory system of the nasolabial fold, potentially representing one factor responsible for the age-related prolapse of cheek fat over the fold.

Mitz and Peyronie[3] have described the fascial dermal attachments that form the crease of the nasolabial fold to be extensions of the SMAS. Our findings do not support this conclusion. On gross and histologic sections, the dermal fascial attachments arising from the nasolabial fold were consistently found to originate from the underlying facial muscles (predominantly the levator labii superioris alaeque nasi and orbicularis oris) and to interdigitate with the fat pads of the middle third of the melolabial fold.

The statement that fibrous extensions of the SMAS insert into the nasolabial fold may actually be interpreted as consistent with the present data,[3] if the conclusion described in the "Results" section and in this section holds true that the levator labii superioris alaeque nasi may be regarded as the SMAS equivalent in the midface. Then, in fact, the dermal fascial insertions of the nasolabial fold connect the fold with the SMAS equivalent. However, if the function of the SMAS in the midface was under-

stood according to its established definition as a superficial or investing layer, then the present data would not support the notion that extensions of the SMAS insert into the melolabial fold.

To reposition tissues adequately, 3 conditions must be met: The tissue must be adequately mobilized, it must be fixated in the new position, and the inherent viscoelastic properties of the structure must be such that deformation of the structure will not nullify the effects of mobilization and fixation. Based on our findings, it may be theorized that these conditions are not adequately met for the melolabial fold with current surgical techniques.

First, complete mobilization of the melolabial bulge would require subdermal dissection and dissection along the superficial aspect of the buccinator muscle and periosteum. Current techniques do not achieve that. The deep-plane dissection splits the fat of the melolabial bulge in the plane between the malar fat pad and the melolabial extension of the buccal fat pad; the subperiosteal facelift repositions the periosteum over the face of the maxilla but leaves the buccinator muscle not dissected or mobilized. Interestingly, Millard et al[12] suggested that the best way to improve the melolabial fold was to perform a long subdermal skin flap, a maneuver that completely releases the superficial attachments of the melolabial fat.

Second, the 3 structures that can potentially transmit tension to a mobilized melolabial bulge are the overlying skin (superficial), the buccinator muscle (deep), and the levator labii superioris alaeque nasi muscle (in the center). The amount of tension that can be applied to a long skin flap is limited by its extensibility and risk of untoward scarring. To date, no procedure has been described to plicate or shorten the buccinator muscle, and functional limitations may render such a procedure difficult. We are also not aware of a procedure that would apply tension to the levator labii superioris alaeque nasi, which may in fact have an untoward effect by deepening the nasolabial fold as tension is transmitted to its dermal attachments.

Third, even if the fat compartments comprising the melolabial bulge were to be fully mobilized, their inherent viscoelastic properties may be such that deformation of these tissues over time will result in recurrent prolapse and re-creation of the melolabial bulge and fold.

SUBLEVATOR SPACE AND FAT PAD

Another finding of the present study is the description of the sublevator space, which harbors the sublevator extension of the buccal fat pad. This space and fat pad seem to serve 2 important functions. First, the fat may act as a gliding pad for the overlying levator labii superioris alaeque nasi muscle. The extensive bony attachments of the muscle explain the somewhat restricted mobility of its dermal attachments to the upper third of the melolabial fold. Second, the sublevator space and fat seem to protect the infraorbital foramen and nerve (Figure 3B). The melolabial extension of the buccal fat pad abuts the overlying malar fat pad. Together, these fat pads provide the volume of the melolabial bulge, which descends with time to prolapse over the melolabial fold.

The buccal extension of the buccal fat pad seems to serve an important function as well. This fat extends under the zygomaticus muscle group to abut the body of the buccal fat pad laterally. The buccal extension of the buccal fat pad seems to act as the gliding pad for the zygomatici muscles, thus facilitating elevation and lateralization of the corner of the mouth when a person smiles.

Our findings suggest that the body of the buccal fat pad and its more medial extensions (buccal, sublevator, and melolabial) represent an anatomic unit with a homogeneous, somewhat dark and coarse tissue quality. The transition to the pterygoid extension of the buccal fat pad at the level of the ramus of the mandible is distinctly delineated by a fascia. The pterygoid extension of the buccal fat pad is whiter and softer.

The buccal fat pad with its extensions has been studied extensively.[27-31] Stuzin et al[16] describe the buccal extension of the buccal fat pad as the most superficial segment of the buccal fat pad that overlies the buccinator muscle and imparts fullness to the cheek. Its anterior limit is marked by the facial vessels. Rohrich and Pessa[32] elegantly report on the compartments of the facial fat and also discuss a deep facial fat compartment. Their dissection and description of the "deep midfacial fat" seems to correspond to the description by Stuzin et al[16] of the buccal extension of the buccal fat pad, a deep fat pad lateral to the facial vessels, overlying the buccinator muscle and periosteum of the maxilla. Rohrich and Pessa[32] also point out that this fat pad contributes to the nasolabial fat, an observation that concurs with our finding that the melolabial extension of the buccal fat pad contributes substantially to the melolabial bulge.[16,32]

Important differences between our findings and the independent findings of Rohrich and Pessa[32] include our observation that the melolabial extension of the buccal fat pad is part of, and in continuity with, the buccal fat pad, located medial to the buccal extension of the buccal fat pad, which has its anterior limit at the level of the facial vessels. Rohrich and Pessa[32] describe the deep midfacial fat as a separate, not previously reported, compartment. Furthermore, we have observed that the melolabial bulge ("nasolabial fat" in the report by Rohrich and Pessa[32]) does not represent a single compartment but rather is formed by 2 compartments, the overlying malar fat pad and the underlying melolabial extension of the buccal fat. The article by Rohrich and Pessa[32] is remarkable in that it describes a compartmentalization of the subcutaneous (malar) fat pad into nasolabial, medial, middle, and lateral-temporal compartments. Although our study did not address the composition of the subdermal (malar) fat, our observation that fascial insertions radiate along the medial aspect of the malar fat pad and the melolabial extension of the buccal fat pad and that these fasciae lend support to melolabial bulge ("nasolabial fat") is in agreement with the extensive descriptions by Rohrich and Pessa[32] of the intercompartmental fascial condensations of the malar fat pad(s).

In conclusion, this study represents an attempt to address some of the unanswered questions of the surgical anatomy of the midface and melolabial fold. Our findings challenge established concepts. The SMAS does not seem to exist as a separate structure in the midface but rather to form a discontinuous muscle plate with the

zygomatici and levator labii superioris alaeque nasi muscles. The finding of a zone of fusion between the SMAS and the buccinator muscle may explain the resistance of the area lateral to the modiolus to dissection and also the marked effect of tension applied to the SMAS flap on the inferior aspect of the melolabial fold and corner of the mouth. The description of the sublevator space and sublevator extension of the buccal fat pad may prove useful as surgical landmarks and didactic guides to better understand the layered architecture of the midface. The extensions of the buccal fat pad seem to serve important functions as gliding pads and protectors of important structures. The division of the melolabial fold into thirds based on its underlying anatomy may also be of didactic value. More important, an understanding of its layered architecture with its relation to surrounding structures may help to better understand its resistance to surgical rejuvenation.

Accepted for Publication: October 3, 2007.
Correspondence: Holger G. Gassner, MD, Division of Facial Plastic Surgery, Department of Otorhinolaryngology, University of Regensburg, Franz-Josef-Strauss-Allee 11, Regensburg 93042, Germany (gassner@facial-plastic-surgery.eu).
Financial Disclosure: None reported.
Author Contributions: *Study concept and design:* Gassner, Rafii, Murakami, and Larrabee. *Acquisition of data:* Gassner, Rafii, Young, and Moe. *Analysis and interpretation of data:* Gassner, Rafii, and Larrabee. *Drafting of the manuscript:* Gassner, Rafii, Murakami, and Larrabee. *Critical revision of the manuscript for important intellectual content:* Gassner, Rafii, Young, Moe, and Larrabee. *Administrative, technical, and material support:* Gassner, Rafii, Murakami, and Larrabee. *Study supervision:* Young, Moe, and Larrabee.
Previous Presentation: This study received the Sir Harold Delf Gillies Award by the American Academy of Facial Plastic and Reconstructive Surgery Fall Meeting; September 18-21, 2007; Washington, DC.
Additional Contributions: Douglas Backous, MD, and the staff of the Listen for Life Center temporal bone laboratory at Virginia Mason Hospital provided work space, instrumentation, and most of the anatomic specimens. Daniel Adams, HT (ASCP), of the Department of Surgical Pathology, Virginia Mason Hospital, provided skillful preparation of the histologic slides. Daniel O. Graney, MD, and the staff of the Department of Anatomy, University of Washington, provided additional dissection facilities and anatomic specimens.

REFERENCES

1. Furnas DW. The retaining ligaments of the cheek. *Plast Reconstr Surg.* 1989;83(1):11-16.
2. Sherris DA, Larrabee WF Jr. Anatomic considerations in rhytidectomy. *Facial Plast Surg.* 1996;12(3):215-222.
3. Mitz V, Peyronie M. The superficial musculo-aponeurotic system (SMAS) in the parotid and check area. *Plast Reconstr Surg.* 1976;58(1):80-88.
4. Skoog TG. *Plastic Surgery: New Methods and Refinements.* Philadelphia, PA: Saunders; 1974.
5. Hamra ST. The tri-plane face life dissection. *Ann Plast Surg.* 1984;12(3):268-274.
6. Baker SR. Triplane rhytidectomy: combining the best of all worlds. *Arch Otolaryngol Head Neck Surg.* 1997;123(11):1167-1172.
7. Kamer FM. One hundred consecutive deep plane face lifts. *Arch Otolaryngol Head Neck Surg.* 1996;122(1):17-22.
8. Psillakis JM, Rumley TO, Camargos A. Subperiosteal approach as an improved concept for correction of the aging face. *Plast Reconstr Surg.* 1988;82(3):383-394.
9. Furnas DW. Strategies for nasolabial levitation. *Clin Plast Surg.* 1995;22(2):265-278.
10. Hamra ST. A study of long-term effect of malar fat repositioning in face lift surgery: short-term success but long-term failure. *Plast Reconstr Surg.* 2002;110(3):940-951.
11. Sherris DA, Otley CC, Bartley GB. Comprehensive treatment of the aging face: cutaneous and structural rejuvenation. *Mayo Clin Proc.* 1998;73(2):139-146.
12. Millard DR, Yuan RT, Devine JW. A challenge to the nasolabial fold. *Plast Reconstr Surg.* 1987;80(1):37-46.
13. Yousif NJ, Gosain A, Matloub HS, Sanger JR, Madiedo G, Larson DL. The nasolabial fold: an anatomic and histologic reappraisal. *Plast Reconstr Surg.* 1994;93(1):70-77.
14. Owsley JQ. Lifting the malar fat pad for correction of prominent nasolabial folds. *Plast Reconstr Surg.* 1993;91(3):463-474.
15. Rubin LR. The anatomy of the nasolabial fold: the keystone of the smiling mechanism. *Plast Reconstr Surg.* 1999;103(2):687-691.
16. Stuzin JM, Wagstrom L, Kawamoto HK, Baker TJ, Wolfe SA. The anatomy and clinical applications of the buccal fat pad. *Plast Reconstr Surg.* 1990;85(1):29-37.
17. Gosain AK, Yousif NJ, Madiedo G, et al. Surgical anatomy of the SMAS: a reinvestigation. *Plast Reconstr Surg.* 1993;92(7):1254-1263.
18. Gray H. *Anatomy of the Human Body.* 29th ed. Philadelphia, PA: Lea & Febiger; 1985:438.
19. Keller GS, Cray J. Suprafibromuscular facelifting with periosteal suspension of the superficial musculoaponeurotic system and fat pad of Bichat rotation: tightening the net. *Arch Otolaryngol Head Neck Surg.* 1996;122(4):377-384.
20. Jost G, Levet Y. Parotid fascia and face lifting: a critical evaluation of the SMAS concept. *Plast Reconstr Surg.* 1984;74(1):42-51.
21. Gasser RF. The development of the facial muscles in man. *Am J Anat.* 1967;120:357.
22. Futamura R. Ueber die Entwicklung der Facialismuskulatur des Menschen. *Anat Hefte.* 1906;30:433-516.
23. Leperchey F. L'embryogéne des muscles faciaux, masticateurs, de la langue, du voile et du cou. *Rev Stomatol Chir Maxillofac.* 1979;80(2):45-67.
24. Seiler R. Criteria of the homology and phylogeny of facial muscles in primates including man, I: prosimia and platyrrhina [in German]. *Gegenbaurs Morphol Jahrb.* 1979;125(2):191-217.
25. Seiler R. Criteria for homology and alleged phylogeny of facial muscles in primates including man, II: catarrhina [in German]. *Gegenbaurs Morphol Jahrb.* 1979;125(3):298-323.
26. Hamra ST. Composite rhytidectomy and the nasolabial fold. *Clin Plast Surg.* 1995;22(2):313-324.
27. Heister L. *Compendium Anatomicum.* Nuremberg, Germany: Weber; 1732.
28. Bichat F. *Anatomie Générale, Appliqué a la Physiologie et a la Médécine.* Paris, France: Grosson Gabon & Cie; 1802.
29. Ranke H. Ein Saugpolster in der menschlichen Backe. *Arch Pathol Anat.* 1884;97:527.
30. Gaughran GRL. Fasciae of the masticator space. *Anat Rec.* 1957;129(4):383-400.
31. Larrabee WF, ed. *Surgical Anatomy of the Face.* Philadelphia, PA: Lippincott Williams & Wilkins; 2004.
32. Rohrich RJ, Pessa JE. The fat compartments of the face: anatomy and clinical implications for cosmetic surgery. *Plast Reconstr Surg.* 2007;119(7):2219-2227.